

Seventy Per Cent Hydrofluoric Acid Burns: Delayed Decontamination With Hexafluorine® and Treatment With Calcium Gluconate

Carlos Alberto Yoshimura, MD,*†‡ Laurence Mathieu, PhD,§ Alan H. Hall, MD,||¶
Mário G. Kool Monteiro, PhD,# Décio Moreira de Almeida

This is a case report of decontamination and treatment of a 70% hydrofluoric acid (HF) dermal splash injury. A worker was splashed with 70% HF, sustaining approximately 10% TBSA first- to third-degree chemical skin burns of the face, trunk, and left thigh and leg. Initial decontamination involved water rinsing, removal of contaminated clothing, more water rinsing, topical application of magnesium oxide, and administration of intravenous narcotics for management of severe pain. After a delay of approximately 3 hours, active skin washing with Hexafluorine®, 5 L, was performed, followed by intravenous, intradermal perilesional, and topical inunction administration of calcium gluconate. Pain relief and a cooling sensation were quite prompt after Hexafluorine® decontamination. Surgical debridement and skin grafting of the more severe burns were required. No significant systemic toxicity developed, although this has occurred in previously reported similar concentrated HF dermal splash exposure cases, some of which resulted in fatality. While burns did develop, the patient was released from the intensive care service after 2 days and, after skin grafting, had a good outcome at 90-day follow-up. Even after a long delay, decontamination with Hexafluorine® appeared to be beneficial in this case. (*J Burn Care Res* 2011;32:e149–e154)

Concentrated hydrofluoric acid (HF) (49–70% or anhydrous) can cause severe skin burns and systemic toxicity. The hydrogen ion (H^+) causes corrosive skin injury, thus allowing the fluoride ion (F^-) to penetrate through the skin and into the circulatory system, resulting in significant systemic poisoning and cardio-

vascular collapse by binding to serum calcium and magnesium and releasing potassium from red blood cells.^{1,2} In addition, HF is a small molecule (molecular weight = 20) which is only partially dissociated on the skin surface ($pK_a = 3.2$) and thus capable of penetrating deeply into the tissues of the skin before dissociating into corrosive (H^+) and locally and systemically toxic (F^-) ions.

Cases of dermal exposure to concentrated HF have sometimes had fatal outcomes.^{3–9} Concentrated HF splashes on the face or the groin area of 1 to 2% TBSA have also rarely been fatal.¹⁰

*From the *SAMU 192 (Mobile Emergency Service) of the Cubatão Municipality, São Paulo, Brazil; †Universidade Católica de Santos, UNISANTOS, São Paulo, Brazil; ‡Service of Plastic Surgery and Burns, Santa Casa de Santos, São Paulo, Brazil; §Scientific Action Group, Laboratoire Prevor, Valmondois, France; ||Toxicology Consulting and Medical Translating Services, Inc., Laramie, Wyoming; ¶Colorado School of Public Health, Denver; and #Globaltek, Salvador, Bahia, Brazil.*

Supported by Laboratoire Prevor, Valmondois, France, manufacturer of Hexafluorine®, for translation of this manuscript from the Portuguese and editing for publication in English.

*A version of this article was previously published in Portuguese: Yoshimura CA, Mathieu L, Hall AH, Monteiro MGK, Moreira de Almeida D. Queimadura por ácido hidrofúorídrico e descontaminação com quelante anfótero e gluconato de cálcio: relato de caso. *Revista Brasileira de Queimaduras (RBQ)* 2009; 8:106–9.*

This English version is published with the permission of the original Brazilian publisher and the authors.

Drs. Yoshimura and Hall are consultants to Laboratoire Prevor, Valmondois, France, manufacturer of Hexafluorine®. Dr. Mathieu is an employee of Laboratoire Prevor. Address correspondence to Alan H. Hall, MD, Toxicology Consulting and Medical Translating Services, Inc. (TCMTS, Inc.), 1050 North 3rd Street, Suite H, Laramie, WY 82072. Copyright © 2011 by the American Burn Association. 1559-047X/2011

DOI: 10.1097/BCR.0b013e31822240f7

Current recommendations in such cases are for decontamination with copious amounts of potable water (water suitable for drinking)¹¹ and topical application of 2.5% calcium gluconate gel by inunction, although topical application of various magnesium compounds or iced benzalkonium chloride¹² have also been used. However, water decontamination of chemical skin splashes may not always be efficacious.¹³

Hexafluorine® (Laboratoire Prevor, Valmondois, France) is an active decontamination solution specifically designed for prevention or mitigation of HF chemical burns.¹⁴ The following case report, when compared with historical controls, suggests that Hexafluorine® use may be of interest in cases of concentrated HF skin exposure, even after initial water washing and with delayed application.

CASE REPORT

A 38-year-old worker was splashed with approximately 4 L of 70% HF on the face, trunk, and left thigh and leg. Initial decontamination while still clothed was with tap water for a few minutes. Clothing was then removed and further water washing was performed in an industrial safety shower. After transport to a nearby medical facility, magnesium oxide was applied topically and gauze dressings were applied to the thigh and leg injuries. Intravenous narcotics were administered for severe pain.

Because of the remote location where the injury occurred, it was only approximately 3 hours after the HF splash that the active topical decontamination solution, Hexafluorine®, became available. First-, second-, and third-degree burns had already developed by this time (Figures 1 to 3).

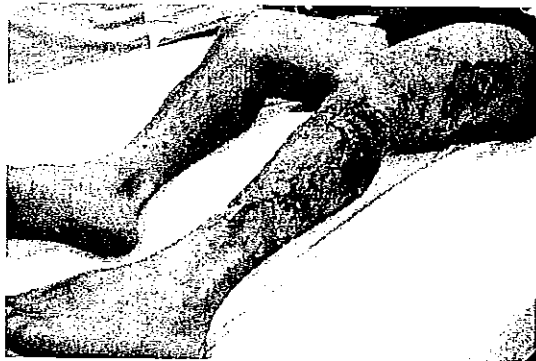


Figure 1. After water decontamination but before Hexafluorine® decontamination, first-, second-, and third-degree HF burns had already developed.



Figure 2. Third-degree HF burn on the thigh.

After 5 L of Hexafluorine® were applied topically over 5 to 6 minutes (Figure 4), the patient reported a cooling sensation, pain relief, and erythema noted on the face rapidly resolved.

Calcium gluconate was then administered intravenously (40 ml of 10% calcium gluconate in 500 ml of normal saline), by intradermal perilesional injection (10% calcium gluconate), and by topical inunction of 2.5% calcium gluconate into the burn lesions (Figures 5, 6).

Surgical debridement of the more severe burns (Figure 7) was required. Skin grafting was required and resulted in a good outcome within 90 days (Figure 8). The patient was able to be released from the intensive care unit on the second hospital day. No significant systemic toxicity developed, as has been previously reported in similar cases, although there were minimal changes in serum calcium (lowest value 7.9 mmol/L; normal: 8.5–10.5 mmol/L) and serum magnesium (lowest value 1.4 mmol/L; normal: 1.9–2.5 mmol/L). Metabolic acidosis did not occur as




Figure 3. First-degree HF burns on the abdomen.

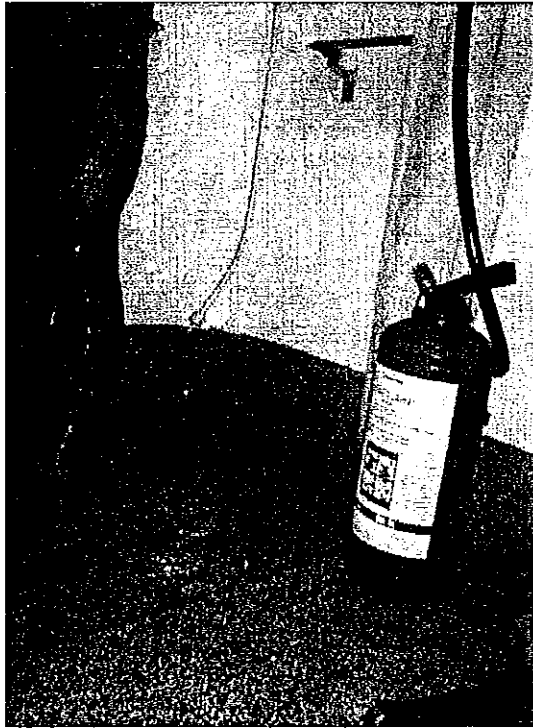


Figure 4. Delayed (approximately 3 hours after HF exposure) Hexafluorine[®] decontamination.

shown by normal arterial blood gas values. Chest x-rays remained normal.

DISCUSSION

Experimental studies have been published in which various decontamination solutions were tested for the ability to decrease the severity of dermal burns after HF exposure.¹² The most widely recommended de-



Figure 5. Topical application (by inunction) of calcium gluconate.

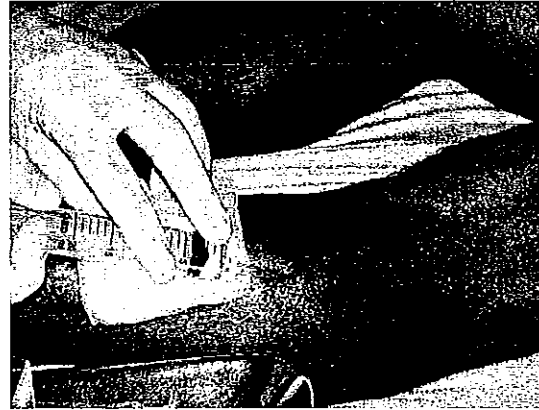


Figure 6. Perilesional intradermal infiltration of calcium gluconate.

contamination method is initial water decontamination followed by topical inunction of 2.5 to 3% calcium gluconate gel, although iced benzalkonium chloride is also frequently used in industrial settings. Water washes unabsorbed HF off the exposed skin while the calcium ion (Ca^{+2}) from calcium gluconate binds the fluoride ion (F^-) as calcium fluoride (CaF_2), mitigating its local skin and systemic toxic effects. These properties of water washing and calcium gluconate have previously brought about significant improvement in the management of HF splashes.

However, published clinical cases of use of water plus calcium gluconate initial decontamination and treatment for concentrated HF splashes have described severe dermal burns and/or systemic toxicity, including death. Sheridan et al¹⁵ reported the case of a worker who had a 5% TBSA (abdomen, right thigh) splash with anhydrous HF. Despite immediate water

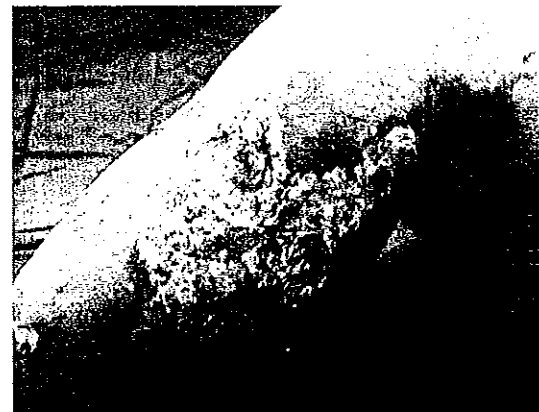

Figure 7. Surgical debridement of burn lesions on the second hospital day.




Figure 8. Appearance of left thigh and leg at 90 days after skin grafting, showing good healing.

decontamination and subcutaneous injection of 10% calcium gluconate, a deep burn developed requiring surgical excision and skin grafting. Nguyen et al¹⁰ reported the case of a maintenance worker who was splashed when a pipe containing anhydrous HF burst, spraying him on the right face and ear. Despite immediate water decontamination and application of benzalkonium chloride, a significant burn developed requiring surgical intervention. Of note, the patient was treated with infusion of 10% calcium gluconate into the right external carotid artery, which did not prevent the burn from developing.¹⁰

Serious systemic HF poisoning has been survived in some cases.¹⁶⁻¹⁹ However, severe electrolyte abnormalities (hypocalcemia, hypomagnesemia, and hyperkalemia) and significant metabolic acidosis have frequently occurred,^{17,20-23} sometimes resulting in ECG abnormalities and often dysrhythmias such as torsades de pointes ventricular tachycardia, ventricular fibrillation, or other nonperfusing ventricular dysrhythmias.^{16,20,22,24,25} Healing time may be quite long in nonfatal HF exposure cases, and lost work time has ranged from 24 to 50 days up to 1 year when standard water decontamination and treatment with calcium salts has been done.²⁴⁻²⁷

Several fatal cases involving exposure to concentrated HF on about 10% or more of the TBSA have been reported, even when immediate water decontamination was done followed by varying treatments with calcium salts (topical or parenteral).^{6,8,28,29} In general, these reported cases involved dermal and/or inhalation exposure to HF in concentrations >50% (usually 60%, 70%, or anhydrous). Facial skin exposures are particularly dangerous, and deaths have been reported at these concentrations when only about 2.5% or less of TBSA was involved.

Water decontamination provides only mechanical rinsing and dilutional actions and may have a hypotonic "wash-in effect" increasing skin penetration,^{13,30} thus having only passive actions. While the action of water decontamination is limited to mechanical and dilutional effects, it can increase the chances of survival despite involved TBSA >10%.^{31,32}

Hexafluorine[®] is an active decontamination solution.^{14,24,33,34} It is not irritating to the eyes and skin and is nonsensitizing and nontoxic. Hexafluorine[®] is water soluble, supplied as a sterile solution, and would be expected to have the same dilutional and mechanical rinsing action as a similar volume of water. Hexafluorine[®] binds both the H⁺ and F⁻ ions without significant release of heat.¹⁴ In vitro, 0.2% HF was placed in a beaker and water, 10% calcium gluconate, or Hexafluorine[®] was added.¹⁴ The pH and pF (negative algorithm of the fluoride ion concentration) were measured. At equal volumes, water had little effect on pH, 10% calcium gluconate increased the pH to approximately 4.5, and Hexafluorine[®] increased it to approximately 6.5 (physiological pH). Also at equal volumes, water had little effect on pF, 10% calcium gluconate increased it to approximately 3 (not above the theoretical toxicity limit), and Hexafluorine[®] increased it to approximately 6 (above the theoretical toxicity limit). Thus, in this in vitro model, calcium from calcium gluconate binding of the fluoride ion (F⁻) was insufficient, whereas Hexafluorine[®] binding of the F⁻ ion was sufficient.

Hexafluorine[®] thus provides active dermal decontamination as opposed to passive water decontamination. It has been reported to be effective in 32 workers with eye or skin HF chemical splashes with concentrations ranging from 6% (as "pickling acid"; 6% HF/15% nitric acid) to 70%.^{24,34,35} In a series of 16 cases of HF exposure decontaminated with Hexafluorine[®] at a Swedish metallurgy facility, no systemic toxicity, permanent sequelae, or severe burns were noted.²⁴ Of these HF exposed workers, two were splashed with 70% HF on the left forearm or in the oral cavity. Hexafluorine[®] decontamination was begun within

less than 1 minute in these two cases and only one worker had 1 day of lost work time. In another case series of 11 workers splashed with either 6% HF/15% nitric acid ("pickling acid") or 40% HF at a German metallurgy facility, Hexafluorine® decontamination was associated with an absence of burn lesions, no requirement for any treatment other than decontamination, no sequelae, and no lost work time.³⁴

Among the 32 reported cases of HF splashes decontaminated with Hexafluorine®,³⁵ 5 could have presented a lethal risk based on the criteria by Dünser et al.²⁷ However, no severe burns, systemic toxicity, or sequelae developed in these cases.

Based on results obtained in industrial HF accidents with Hexafluorine® washing as first aid where no severe burns or systemic toxicity have occurred compared with those with water washing followed by topical calcium gluconate where these latter interventions have not always prevented development of severe burns or systemic toxicity, Hexafluorine® initial washing should be considered, especially with concentrated HF splashes. Initial water decontamination and topical application of magnesium oxide were inadequate for removal and inactivation of HF on the skin in the case presented here, as evidenced by the development of burn lesions and severe pain not relieved by administration of intravenous narcotics. That the patient reported pain relief and that no further progression of the skin burns occurred after Hexafluorine® decontamination indicates that residual HF was still present on the skin at about 3 hours after the exposure. As Hexafluorine® has no analgesic or anti-inflammatory properties, pain relief and prevention of lesion progression most likely represented inactivation of residual HF.

In the case presented here, even delayed washing with Hexafluorine® was associated with no further burn evolution and no systemic toxicity. Hexafluorine® is a decontamination solution and not a treatment for HF skin burns.

Hexafluorine® facilitates the successful utilization of such therapeutic agents as calcium gluconate. As shown in the case reported here, a protocol of washing with Hexafluorine® followed by utilization of calcium gluconate should be of interest for the delayed management of concentrated HF skin splashes.

Hexafluorine® is currently available in various African countries, Australia/New Zealand, Brazil, Canada, Chile, China, most of Eastern and Western Europe, India, Israel, Jamaica, Martinique, throughout Scandinavia, and Turkey. It is not currently actively marketed in the United States.

CONCLUSION

In the case reported here, after initial removal of contaminated clothing and copious water skin decontamination, delayed Hexafluorine® skin decontamination (after 3 hours) of a 70% HF splash was associated with no development of systemic toxicity and a good clinical outcome. Because of the delay until active decontamination, the patient did require surgical debridement of the more severe burn lesions and skin grafting. Hexafluorine® deserves consideration for utilization in clinical cases of concentrated HF skin exposure.

REFERENCES

1. Segal EB. First aid for a unique acid, HF: a sequel. *J Chem Health Saf* 2000;7:18–23.
2. Caravati EM. Acute hydrofluoric acid exposure. *Am J Emerg Med* 1988;6:143–50.
3. El Saadi MS, Hall AH, Hall PK, et al. Hydrofluoric acid dermal exposure. *Vet Human Toxicol* 1989;31:243–7.
4. Chataigner RC, Garnier R, Bonin C. Brûlures cutanées et intoxication systémique mortelle secondaires à une projection d'acide fluorhydrique [Cutaneous burns and fatal systemic poisoning secondary to a hydrofluoric acid splash]. *Arch Mal Prof* 1992;53:13–29 [in French].
5. Burke WJ, Hoegg UR, Phillips RE. Systemic fluoride poisoning resulting from a fluoride skin burn. *J Occup Med* 1973; 15:39–41.
6. Mayer TG, Gross PL. Fatal systemic fluorosis due to hydrofluoric acid burns. *Ann Emerg Med* 1985;14:149–53.
7. Chan KM, Svancarek WP, Creer M. Fatality due to acute hydrofluoric acid exposure. *J Toxicol Clin Toxicol* 1987;25: 333–9.
8. Mullet T, Zoeller T, Bingham H, et al. Fatal hydrofluoric acid cutaneous exposure with refractory ventricular fibrillation. *J Burn Care Rehabil* 1987;8:216–9.
9. Ohtani M, Nishida N, Chiba T, Muto H, Yoshioka N. Pathological demonstration of rapid involvement into the subcutaneous tissue in a case of fatal hydrofluoric acid burns. *Forensic Sci Int* 2007;167:49–52.
10. Nguyen LT, Mohr WJ III, Ahrenholz DH, Solem LD. Treatment of hydrofluoric acid burn to the face by carotid artery infusion of calcium gluconate. *J Burn Care Rehabil* 2004;25: 421–4.
11. ANSI/ISEA Z358.1-2009 American National Standard for Emergency Eyewash and Shower Equipment. International Safety Equipment Association, Arlington, Virginia, September 14, 2009.
12. Dunn BJ, MacKinnon MA, Knowlden NF, et al. Hydrofluoric acid dermal burns: an assessment of treatment efficacy using an experimental pig model. *J Occup Med* 1992;34: 902–9.
13. Hall AH, Maibach HI. Water decontamination of chemical skin/eye splashes: a critical review. *Cutan Ocul Toxicol* 2006; 25:67–83.
14. Mathieu L, Burgher F, Blomet J. Comparative evaluation of the active eye and skin chemical splash decontamination solutions Diphoterine and Hexafluorine with water and other rinsing solutions: effects on burn severity and healing. *J Chem Health Saf* 2007;14:32–9.
15. Sheridan RL, Ryan CM, Quinby WC Jr, Blair J, Tompkins RG, Burke JF. Emergency management of major hydrofluoric acid exposures. *Burns* 1995;21:62–4.
16. Bordelon BM, Saffle JR, Morris SE. Systemic fluoride toxicity

- in a child with hydrofluoric acid burns: case report. *J Trauma* 1993;34:437-9.
17. Hatzifotis M, Williams A, Muller M, Pegg S. Hydrofluoric acid burns. *Burns* 2004;30:156-9.
 18. Richter H, Hollenberg S, Sachs H-J, et al. Verätzung mit flusssäure. Ein seltener chemischer Notfall [Hydrofluoric acid poisoning. An unusual chemical emergency]. *Anaesthetist* 2005;54:123-6 [in German].
 19. Sadove R, Hainsworth D, van Meter W. Total body immersion in hydrofluoric acid. *South Med J* 1990;83:698-700.
 20. Björnhagen V, Höjer J, Karison-Stiber C, Seldén AI, Sundbom M. Hydrofluoric acid-induced burns and life-threatening systemic poisoning—favorable outcome after hemodialysis. *J Toxicol Clin Toxicol* 2003;41:855-60.
 21. Kono K, Watanabe T, Dote T, et al. Successful treatments of lung injury and skin burn due to hydrofluoric acid exposure. *Int Arch Occup Environ Health* 2000;73(Suppl):S93-7.
 22. Sanz-Gallén P, Nogué S, Munné P, Faraldo A. Hypocalcemia and hypomagnesaemia due to hydrofluoric acid. *Occup Med (Lond)* 2001;51:294-5.
 23. Greco RJ, Hartford CE, Haith LR Jr, Patton ML. Hydrofluoric acid-induced hypocalcemia. *J Trauma* 1988;28:1593-6.
 24. Soderberg K, Kuusinen P, Mathieu L, et al. An improved method for emergent decontamination of ocular and dermal hydrofluoric acid splashes. *Vet Human Toxicol* 2004;46:216-8.
 25. Segal E. The agonizing effect of hydrofluoric acid exposure: a case study. *J Chem Health Saf* 2008;15:5-6.
 26. Barbier F, Bonnet P, Julie R, et al. Brûlures cutanées par acide fluorhydrique. A propos de 32 cas [Cutaneous burns with hydrofluoric acid. Regarding 32 cases]. *Arch Mal Prof* 1987;48:400-2 [in French].
 27. Dünser MW, Öhlbauer M, Rieder J, et al. Critical care management of major hydrofluoric acid burns: a case report, review of the literature, and recommendations for therapy. *Burns* 2004;30:391-8.
 28. Hung OL, Floenbaum M, Floenbaum NE. Profound ionized hypocalcemia with arrhythmia and coagulopathy in a fatal hydrofluoric acid exposure [Abstract]. *J Toxicol Clin Toxicol* 1998;36:427.
 29. Teppermann PB. Fatality due to acute systemic fluoride poisoning following an hydrofluoric acid skin burn. *J Occup Med* 1980;22:691-2.
 30. Moody RP, Maibach HI. Skin decontamination: importance of the wash-in effect. *Food Chem Toxicol* 2006;44:1783-8.
 31. Kirkpatrick JJR, Burd DAR. An algorithmic approach to the treatment of hydrofluoric acid burns. *Burns* 1995;21:495-9.
 32. Kirkpatrick JJR, Enion DS, Burd DAR. Hydrofluoric acid burns: a review. *Burns* 1995;21:483-93.
 33. Hall AH, Blomet J, Gross M, et al. Hexafluorine for emergent decontamination of hydrofluoric acid eye/skin splashes. *Semiconductor Safety Assoc J* 2000;14:30-3.
 34. Mathieu L, Nehles J, Blomet J, et al. Efficacy of Hexafluorine for emergent decontamination of hydrofluoric acid eye and skin splashes. *Vet Human Toxicol* 2001;43:263-5.
 35. Mathieu L, Barbe JM, Blomet J. Efficient first aid decontamination of major hydrofluoric acid exposures with Hexafluorine® [Abstract]. Presented at EUROTOX 2000, London, UK, September 17-20, 2000.